

Making Memories: Supportive Care of an Infant with a Type IV Laryngotracheoesophageal Cleft

CM McDougall^{1,2}, M-L Montague³, P Smith¹, J McCormack¹, J McFadzean¹

¹Paediatric Intensive Care Unit, ²Department of Respiratory Paediatrics, ³Department of Paediatric Otolaryngology, Royal Hospital for Sick Children, Edinburgh, UK

Introduction

The importance of palliative care in paediatric critical care, especially for patients with life-limiting conditions, is increasingly recognised¹. We describe our supportive care of an infant with a lethal congenital malformation, which maintained stability for 3 months while clinical management decisions were made. This enabled his family to spend quality time with him and make invaluable memories.

Case Report

A male infant was delivered at term after a pregnancy complicated by polyhydramnios and absent stomach on antenatal ultrasound. Postnatal contrast study showed a hiatus hernia and gastro-oesophageal reflux with aspiration. An orojejunal feeding tube was passed and a replogle tube placed with the tip in the gastric fundus. Microlaryngoscopy/bronchoscopy on day 6, performed because of CPAP dependency and aphonic cry, showed a type IVb laryngotracheoesophageal cleft (LTOC)^{2,3} (Figure 1). Tracheo-bronchomalacia was evident. At 13 weeks, surgical repair via an anterior cervical approach with midline sternotomy was undertaken on ECMO. Two weeks later, irreparable distal dehiscence was noted and care was withdrawn.

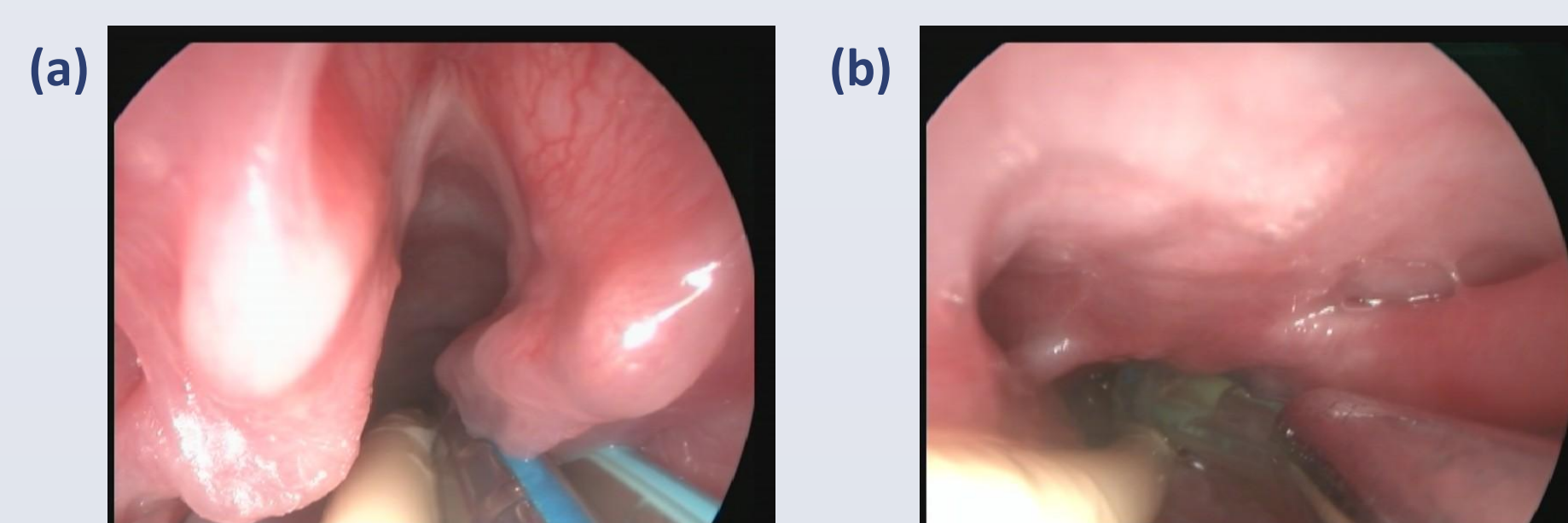


Figure 1: Anatomy of the type IVb LTOC at the level of (a) larynx and (b) origin of left and right main bronchi (carina absent)

Supportive Care

Prior to surgery, the patient was maintained on nasal CPAP in air, with periods off support as tolerated. He received regular chest physiotherapy. He was fed via orojejunal tube. A replogle tube was maintained on constant suction (5kPa), with the tip in the distal oesophagus. The tube was flushed with 1ml 0.9% saline every 15 minutes and as required. An orogastric tube was kept on free drainage with regular aspiration (Figures 2&3). Constant vigilance was maintained regarding the position and patency of these tubes.

Portable replogle suction was achieved with a Laerdal suction unit on the lowest setting (80mmHg/10.7kPa) which allowed him to leave PICU for short periods (Figure 4).

The combination of CPAP, chest physiotherapy, replogle suction, jejunal feeding and gastric drainage maintained stability while decisions regarding surgical options were made and enabled an international air transfer for surgical repair. During this time, the patient was able to interact with his family, enjoy cuddles and baths, wear normal clothes and go out for walks both within and outside the hospital.

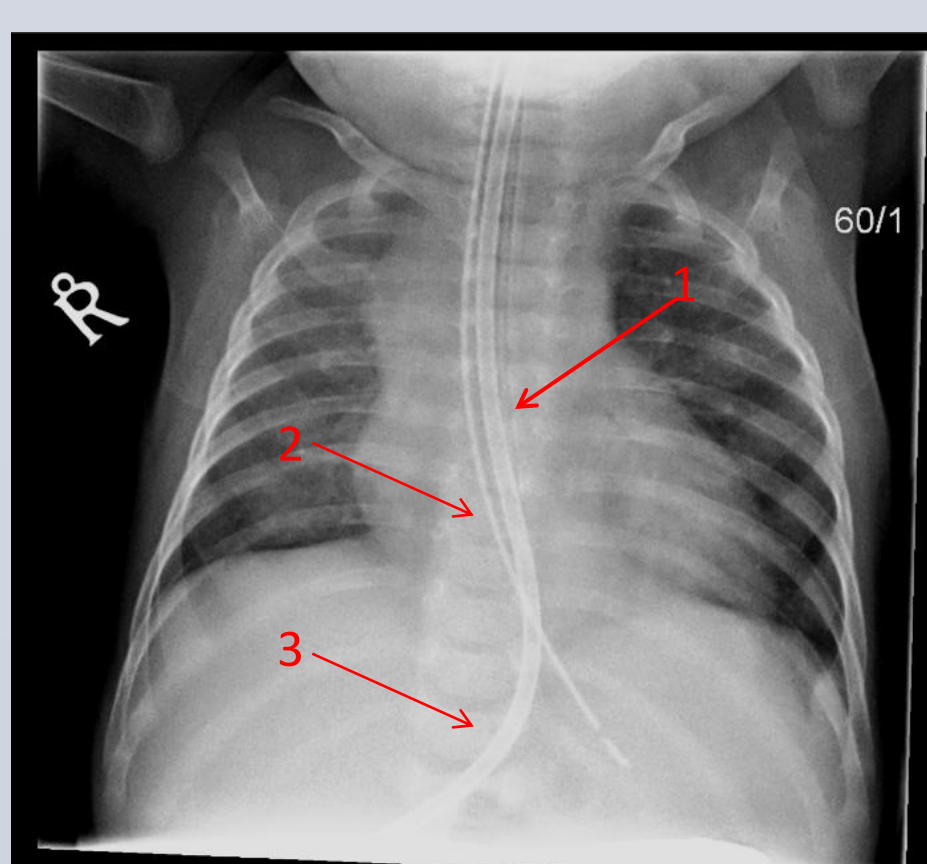


Figure 2: Chest radiograph on day 81 of life, showing replogle tube¹, orogastric tube² and orojejunal tube³. Lung fields show bilateral airspace infiltrate but no confluent collapse or consolidation.

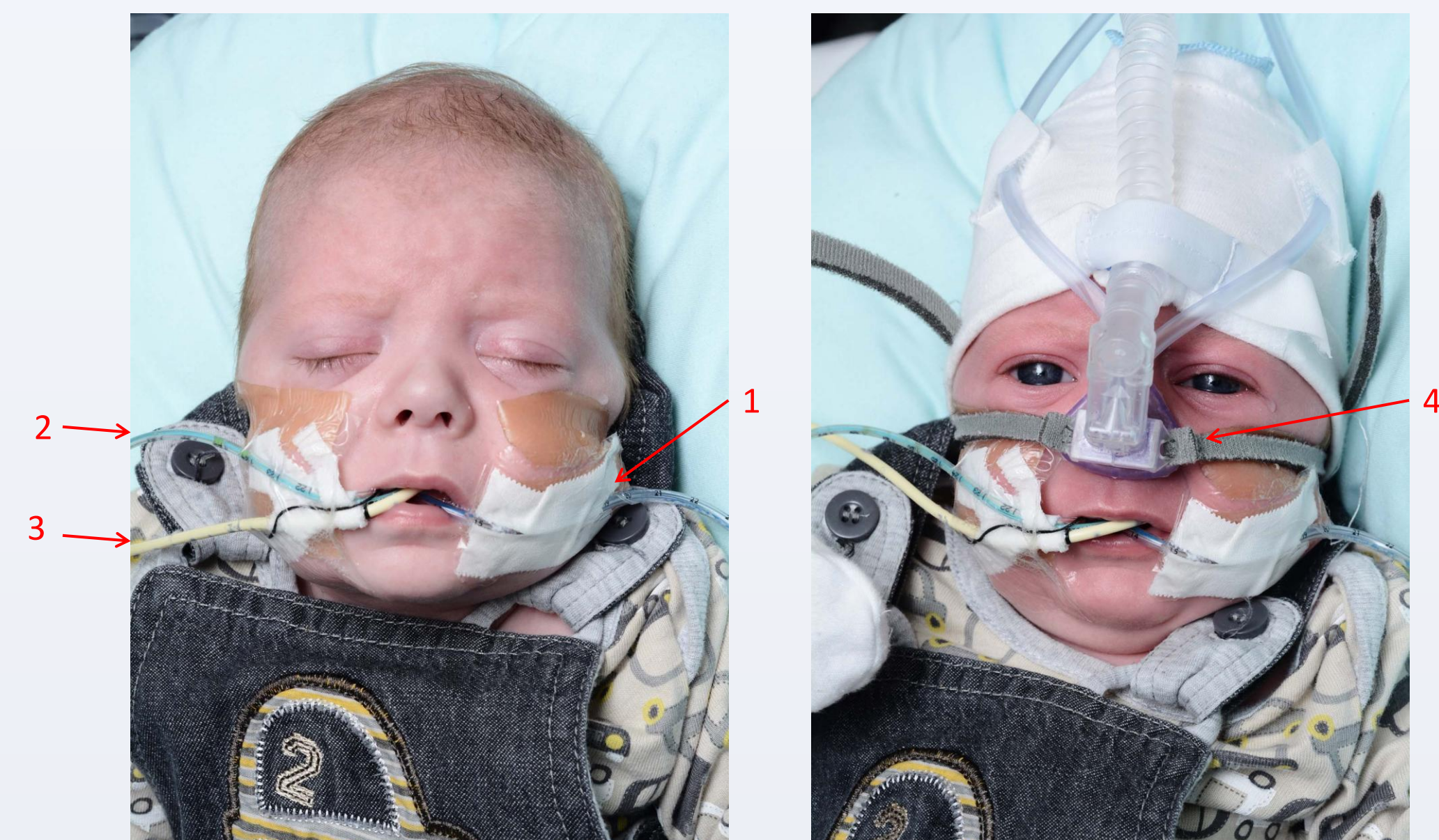

Figure 3: The patient was maintained with replogle tube¹, orogastric tube², orojejunal tube³ and nasal CPAP⁴.




Figure 4: Supportive care set-up to enable patient to leave PICU. Replogle tube¹, orogastric tube on free drainage², orojejunal tube³, portable suction unit for replogle tube⁴, second portable suction unit as spare⁵, saturation monitor⁶, oxygen cylinder⁷ attached to anaesthetic t-piece⁸ for emergency use

Discussion

Double lumen “replogle” tubes were developed for management of oesophageal atresia⁴. Use in LTOC has not previously been described but we believe it was critical in this case in minimising secondary aspiration. The novel combination of replogle suction, jejunal feeding and gastric drainage, along with CPAP and chest physiotherapy, facilitated high quality supportive care in PICU. Following his death, his parents reflected positively on the many happy memories they had of his short life and expressed no regrets about their decision to pursue an innovative surgical option.

This case highlights the important role of PICU staff in promoting family-centred care and intentionally integrating palliative care into the PICU. Pursuit of palliative care is compatible with concurrent pursuit of active treatment, including cutting edge surgery.



Acknowledgements

We would like to thank the patient's parents for their permission to share this case and their consent to use the photographs. The dedication of the bedside nurses in PICU is also acknowledged.

References

1. Boss R *et al*, *Pediatr Crit Care Med* 2014; 15: 762-767
2. Le Boulanger N & Garabedian E-N, *Orphanet J Rare Dis* 2011; 6: 81
3. Sandu K & Monnier P, *Laryngoscope* 2006; 116: 630-634
4. Replogle RL, *Surgery* 1963; 54: 296-297